

Role of the left hemisphere in sign language comprehension

Gregory Hickok,^{a,*} Tracy Love-Geffen,^b and Edward S. Klima^b

^a *Department of Cognitive Sciences, University of California, Irvine, CA 92697, USA*

^b *Salk Institute for Biological Studies, University of California, San Diego, USA*

Accepted 20 November 2001

Abstract

We investigated the relative role of the left versus right hemisphere in the comprehension of American Sign Language (ASL). Nineteen lifelong signers with unilateral brain lesions [11 left hemisphere damaged (LHD) and 8 right hemisphere damaged (RHD)] performed three tasks, an isolated single-sign comprehension task, a sentence-level comprehension task involving simple one-step commands, and a sentence-level comprehension task involving more complex multiclause/multistep commands. Eighteen of the participants were deaf, one RHD subject was hearing and bilingual (ASL and English). Performance was examined in relation to two factors: whether the lesion was in the right or left hemisphere and whether the temporal lobe was involved. The LHD group performed significantly worse than the RHD group on all three tasks, confirming left hemisphere dominance for sign language comprehension. The group with left temporal lobe involvement was significantly impaired on all tasks, whereas each of the other three groups performed at better than 95% correct on the single sign and simple sentence comprehension tasks, with performance falling off only on the complex sentence comprehension items. A comparison with previously published data suggests that the degree of difficulty exhibited by the deaf RHD group on the complex sentences is comparable to that observed in hearing RHD subjects. Based on these findings we hypothesize (i) that deaf and hearing individuals have a similar degree of lateralization of language comprehension processes and (ii) that language comprehension depends primarily on the integrity of the left temporal lobe. © 2002 Elsevier Science (USA). All rights reserved.

1. Introduction

Lesion studies of the neurobiology of sign language have consistently documented a leftward asymmetry which holds across a range of standard aphasia diagnostic tests (Corina, 1998; Hickok, Bellugi, & Klima, 1998a; Hickok, Klima, Kritchevsky, & Bellugi, 1995; Hickok, Klima, & Bellugi, 1996a; Kimura, 1981; Poizner, Klima, & Bellugi, 1987). Left hemisphere damaged (LHD) signers produce significantly more sign errors (paraphasias) in their production than do right hemisphere damaged

* Corresponding author. Fax: +949-824-2307.

E-mail address: gshickok@uci.edu (G. Hickok).

(RHD) signers, and LHD signers perform significantly more poorly than RHD signers on naming tasks, repetition tasks, and word (sign) and sentence-level comprehension tasks (Hickok et al., 1996a). The differences observed in these studies cannot be explained in terms of group differences in age of onset of deafness, age of exposure to sign language, or age at testing (Hickok et al., 1996a). Furthermore, the left–right asymmetries hold up even when only native deaf signers are included in the analysis (see Fig. 1). The only linguistic deficits that have been identified in right-handed RHD signers are deficits that involve extragrammatical processes, such as producing an appropriately connected discourse (Hickok et al., 1999; Poizner & Kegl, 1993). Extragrammatical linguistic deficits have also been documented in hearing RHD patients (Brownell, Potter, Bihrlé, & Gardner, 1986; Wapner, Hamby, & Gardner, 1981). All of the available lesion evidence, then, points to the conclusion that signed and spoken language have comparable lateralization patterns.

In the context of this body of lesion work, a recent functional imaging study of sign language perception (Neville et al., 1998) has led some authors to claim that comprehension of ASL may be more bilaterally organized than that of spoken language (Neville et al., 1998; Paulesu & Mehler, 1998). In that study, native deaf signers were shown video clips of a person producing American Sign Language sentences alternating with video clips of a person producing sequences of meaningless signlike gestures. A comparison of the two conditions yielded significant activations in a majority of the participants in several regions, including sites in the posterior and anterior temporal lobe; lateral frontal cortex, including Broca's area and its right hemisphere analog; and the angular gyrus, all bilaterally. Although similar regions have been reported to be active while hearing/speaking participants *listen* to spoken language sentences, including bilateral activations in superior temporal gyrus (Binder et al., 1994; Mazoyer et al., 1993; Schlosser, Aoyagi, Fulbright, Gore, & McCarthy, 1998), the reported absence of any hemispheric asymmetry in the distribution of activated regions led some to conclude that the perception of sign language by deaf signers relies on the right hemisphere to a greater extent than does the perception of spoken language by hearing/speaking individuals (Neville et al., 1998; Paulesu & Mehler, 1998). It has been pointed out, however, that there are some methodological problems with the Neville et al. study, and therefore such claims may be premature (Hickok, Bellugi, & Klima, 1998b). For example, activation patterns associated with viewing sign language sentences (deaf group) were compared with activation patterns associated with reading English sentences (hearing group). Yet, these conditions differ along several dimensions beyond the contrast of interest (English vs ASL), including the presence of prosodiclike information in the ASL but not the English stimuli and the presence of nonlinguistic information associated with viewing the signer (e.g., facial expression and nonlinguistic gestures). These confounds need to be controlled by contrasting ASL comprehension with the comprehension of spoken language produced by a visible speaker.

The goal of the present study was to use the lesion method to address empirically the question of the degree of hemispheric asymmetry for the comprehension of sign language. An additional goal was to assess the role of the temporal lobes in ASL comprehension. The left temporal lobe has been implicated as the primary substrate for spoken language comprehension (Naeser, Helm-Estabrooks, Haas, Auerbach, & Srinivasan, 1987), and in the Neville et al. study, temporal lobe structures were activated during ASL comprehension. Parietal lobe structures did not appear to be reliably activated in deaf signers viewing ASL sentences. If the left temporal lobe is particularly important for comprehension of sign language, we expect that patients with damage to the left temporal lobe will have the most severe ASL comprehension deficits.

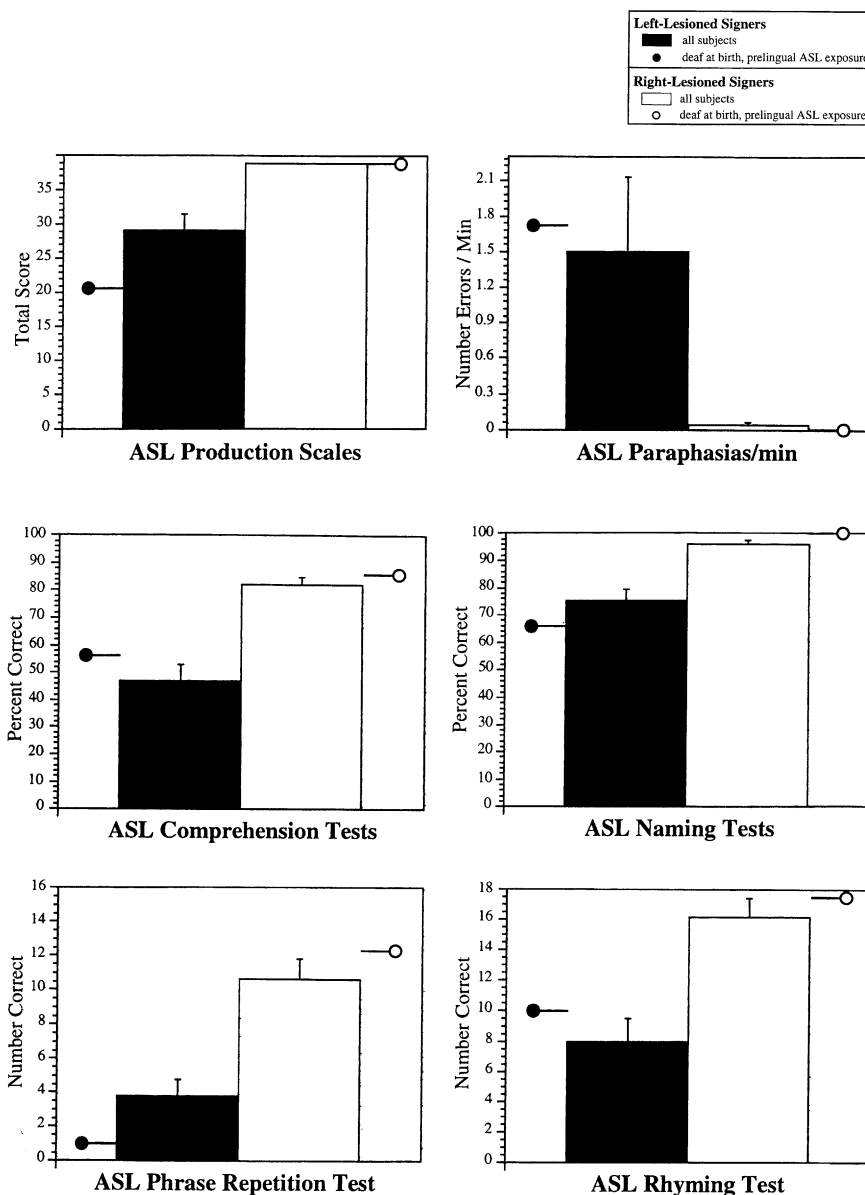


Fig. 1. Means and standard error bars for LHD ($n = 13$) versus RHD ($n = 10$) signers on six measures of ASL ability. Circles indicate level of performance among the subset of this study population who were prelingually deaf native signers (LHD, $n = 4$; RHD, $n = 3$). *Production Scales*: sum score on our ASL-adapted version of the BDAE. *Paraphasias/minute*: total number of sign errors in a sign sample elicited according to BDAE protocol. *Comprehension Tests*: BDAE Commands subtest and our ASL-adapted version of the Token Test (DeRenzi & Vignolo, 1962); two subjects (1 LHD and 1 RHD) did not take these tests. *Naming Tests*: BDAE Visual Confrontation and Responsive Naming tests. *Phrase Repetition Test*: ASL version of the BDAE Phrase Repetition test. *Rhyming Test*: a “rhyme” judgment test in which subjects choose (from an array of four) the two pictured objects whose signs were most similar in terms of sign-phonological features (Poizner et al., 1987); $n = 10$ LHD and 7 RHD.

In the present study, we assessed the comprehension ability of 19 unilaterally brain damaged lifelong signers (11 with left hemisphere damage and 8 with right hemisphere damage) using three measures: a test of single, isolated sign comprehension; a test of syntactically simple sentence-level comprehension; and a test of

complex sentence-level comprehension. Performance on these three tests was evaluated in relation to two variables: the hemisphere involved (left vs right) and whether the temporal lobe was involved. We hypothesized that (i) the LHD group would perform more poorly than the RHD group on all tests and (ii) the LHD +post_temporal group (those *with* temporal lobe damage) would be more impaired than the LHD –post_temporal group (those *without* temporal lobe damage).

2. Methods

2.1. Subjects

Nineteen unilaterally brain damaged subjects participated in this study, 11 with left hemisphere damage and 8 with right hemisphere damage. All were lifelong users of American Sign Language, and all but 1 RHD participant was deaf. Results did not change if the hearing signer was excluded from the analysis. All subjects were tested chronically, at least 1 year after the lesion was acquired. For purposes of analysis, each participant was classified as having a lesion which substantially involved the posterior temporal lobe or did not, based on chronic CT¹ or MRI data (>1 year postlesion except for three cases, RHD10, LHD02, and LHD09, which were acquired at 2, 2.5, and 3 months, respectively), thus yielding four groups: LHD +post_temporal, LHD –post_temporal, RHD +post_temporal, and RHD –post_temporal. Four participants, 3 LHD and 1 RHD, had borderline posterior temporal lobe involvement. These borderline cases were classified as –post_temporal. A separate analysis of the LHD participants grouped in a three-way classification (+, ±, –post_temporal) is presented under Section 3. Most of the +post_temporal participants also had significant involvement of the parietal lobe. This issue is addressed under Section 4. Relevant biographical and medical information is presented by Table 1.

2.2. Stimuli and procedure

Participants were administered two tests of ASL comprehension as part of a larger program investigating the neural organization of sign language. The first test was a single-sign comprehension measure in which the subject was presented with an ASL sign and asked to point to the corresponding picture from an array of 18 items. This test is adapted from the “Word Discrimination” subtest of the Boston Diagnostic Aphasia Examination (BDAE; Goodglass & Kaplan, 1983) and was given according to the BDAE protocol. There were 36 items on this test. The second test was an ASL adapted version of the Token Test (DeRenzi & Vignolo, 1962)—a test in which the subject is asked to carry out “verbal” commands of varying complexity involving a set of colored tokens of different shape. There were 22 items on this test. All testing was carried out by deaf, native signers.

2.3. Scoring

Our interest was in examining the neurobiology of comprehension of ASL simple sentences and lexical signs. For this reason we divided the Token Test items into two groups: the *simple* items comprised six one-clause, one-step commands,

¹ We used CT scans, rather than MRI in some cases, because many of the subjects in our cumulative research program were tested when MRI was not readily available.

Table 1
Subject biographies

	Age of sign exposure	Onset deafness	Gender	Handedness	Age at testing	Imaging modality	Lesion size/location	Lesion etiology
Left lesioned								
LHD01	6	5	m	r	81	CT	Ig/frontal-parietal ^a	Ischemic infarct
LHD02	5	5	f	r	66	CT	mod/inf parietal ^a	Ischemic infarct
LHD03	0	0	f	r	37	CT	Ig/frontal	Ischemic infarct
LHD04	6	1	f	r	51	CT	sm/inf-ant frontal	Aneurism rupture ^b
LHD05	13	0	m	r	45	MR	Ig/temp-par	Hematoma
LHD06	0	0	m	r	77	CT	mod/frontal-temp-par	Ischemic infarct
LHD09	7	<1	m	r	29	CT	mod/frontal-par	Hematoma ^b
LHD10	0	2	f	r	79	MR	mod/inf-post frontal	Ischemic infarct
LHD11	9	<1	f	r	73	MR	mod/frontal-par ^a	Ischemic infarct
LHD12	11	0	f	r	79	MR	Ig/frontal-temp-par	Ischemic infarct
LHD13	4	0	m	r	71	MR	mod/inf frontal-par	Hematoma
Right lesioned								
RHD01	12	0	f	r	71	CT	Ig/front-temp-par	Ischemic infarct
RHD02	9	5	m	r	82	CT	mod/temp-par	Ischemic infarct
RHD03	5	0	m	r	60	MR	Ig/front-temp-par	Ischemic infarct
RHD04	0	0	f	r	61	CT	mod/sup front-par	Tumor ^b
RHD05	0	n/a	f	r	38	MR	mod/sup par-occ	Hematoma ^b
RHD06	0	0	m	r	74	MR	Ig/front-temp-par	Ischemic infarct
RHD08	7	<1	m	r	74	MR	Ig/frontal-temp-par	Ischemic infarct
RHD10	0	0	f	r	78	CT	mod/par-occ ^a	Ischemic infarct

^a Borderline temporal lobe lesion.

^b Surgical intervention.

such as the ASL equivalent of “point to any square” or “point to the white circle.” The *complex* items comprised 16 mult clause and/or multistep commands, such as “touch all the circles except the yellow circle” or “put the black circle on top of the red square.” A score of 2 was given for each Token Test command that was correctly carried out on the first stimulus presentation. If an error was made on the first presentation, the stimulus sentence was provided a second time. A correct response on this second presentation was given 1 point. A score of zero was given if the participant failed on both presentation of a stimulus sentence. Thus, the maximum possible score on the *simple* subset of items was 12, and the maximum possible score on the *complex* subset was 32. The single-sign comprehension test was scored by assigning 1 point for each correct response, for a maximum of 36 points. No repetitions were allowed. One RHD participant (RHD08) did not take the complex portion of the Token Test.

3. Results

On the single-sign comprehension test, performance was quite good with an overall level of 94% correct. The only group showing any substantial variability was the LHD +post_temporal group, which performed at a mean of 79% correct. The proportion correct for each of the four groups is presented in Fig. 2 (top). An analysis of variance (ANOVA) was carried out on these data with hemisphere (left vs right) and temporal lobe involvement (+post_temporal vs –post_temporal) entered as factors. The main effect of hemisphere approached significance [$F(1, 15) = 3.43, p = .084$], and there was a main effect of temporal lobe involvement [$F(1, 15) = 5.09, p = .039$], but the interaction did not reach significance ($p = .22$). Planned comparisons revealed a significant difference between the LHD +post_temporal group and the LHD –post_temporal group ($p = .03$) and a trend toward worse performance by the LHD +post_temporal group than the RHD –post_temporal group ($p = .11$). The borderline significance values in portions of this analysis are no doubt due to the near-ceiling effect on single-sign comprehension.

The sentence-level stimuli yielded the same general pattern but with much more robust differences. On the *simple* subset of the Token Test all but the LHD +post_temporal group performed at or near ceiling: The LHD +post_temporal involvement group scored at 53% correct, whereas the other three groups each scored better than 95% correct. An ANOVA on these data showed significant main effects of hemisphere [$F(1, 15) = 21.44, p = .0003$] and temporal lobe involvement [$F(1, 15) = 23.00, p = .002$]. The interaction also proved highly reliable [$F(1, 15) = 15.72, p = .001$]. The means are presented in graph form in Fig. 2 (middle). The performance of all four groups declined with the complex subset of the Token Test (Fig. 2, bottom), but group differences were still apparent: The LHD +post_temporal involvement group posted the worst scores (12.5% correct); the LHD –post_temporal involvement group scored somewhat better, but still quite poorly (43% correct); and the two RHD groups performed around the 75% correct level. An ANOVA revealed a significant main effect of hemisphere [$F(1, 14) = 17.44, p < .001$] and no other significant effects.

Three of the LHD participants and one RHD participant had lesions which were borderline in terms of their temporal lobe involvement. In each of the LHD cases, the lesions were primarily frontoparietal, but there was some subcortical extension that might have partially undercut the superior temporal gyrus. In the RHD case, the lesion was primarily occipital-parietal with partial involvement of the angular gyrus. In the analyses reported above these borderline cases were classified as

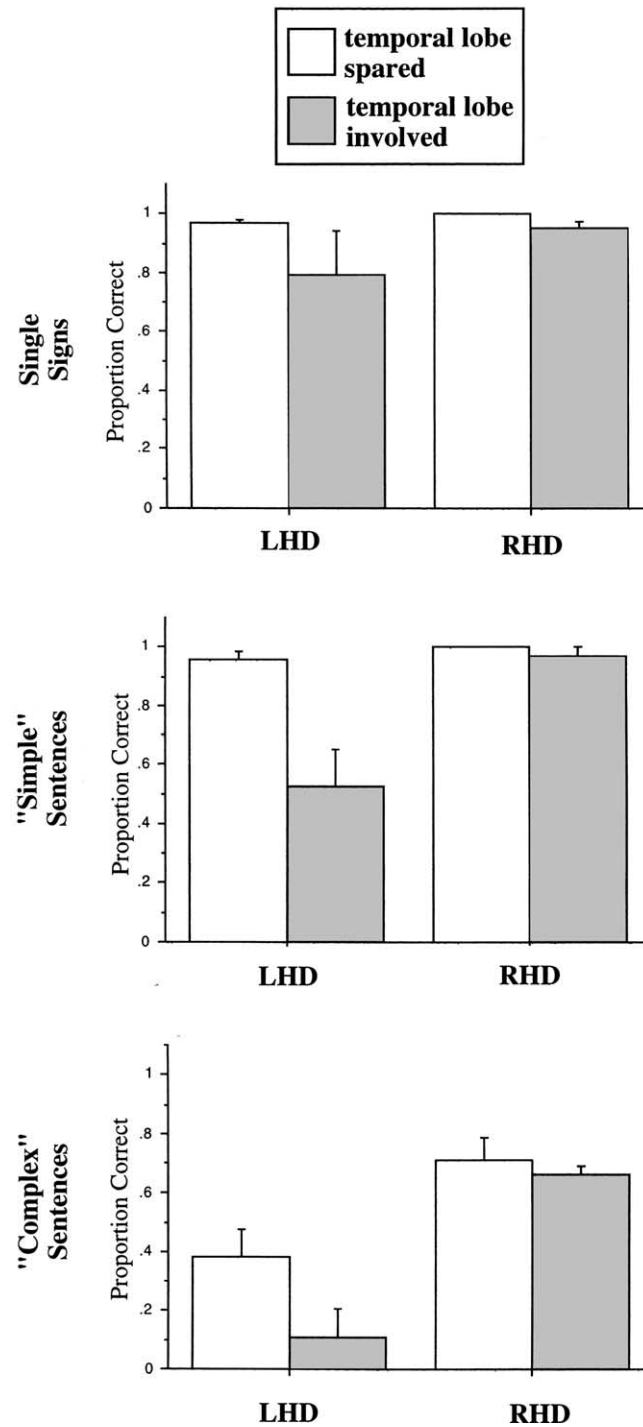


Fig. 2. Comprehension performance in unilateral brain lesioned signers as a function of hemisphere and temporal lobe involvement.

“–post_temporal involvement.” This was done for two reasons, first because the temporal involvement was minimal at most and second because a three-way classification did not afford a large enough N in each subgroup, particularly in the RHD

participants, where only one individual had a borderline temporal lobe lesion. However, because the LHD participants had lesions which fell into the three-way classification with roughly equal *N*s (no temporal involvement = 5, marginal involvement = 3, substantial involvement = 3) we did perform an analysis within the LHD group, in which comprehension of the *simple* Token Test items (i.e., the test which proved to be the best discriminator between groups in previous analyses) was compared among the three groups. Group means went in the expected direction with performance falling off as a function of the degree of temporal lobe involvement. A one-way, three-level ANOVA revealed a highly reliable effect [$F(2,8) = 16.06$, $p = .002$]. The group means of the LHD participants are plotted in Fig. 3 along with the means for the RHD participants for comparison purposes.

Because we could not control precisely the distribution of lesions in the left versus right hemisphere damaged groups, it is possible (although unlikely given the effect sizes) that lesion-related sampling error contributed to the observed left–right differences. To address this problem, we selected two participants with similar temporal lobe/perisylvian lesions, one LHD and one RHD, for direct comparison. There is some difference in the extent of temporal lobe involvement between these two cases, making this comparison less than ideal. However, the RHD signer has a slightly larger temporal lobe lesion which should, if anything, bias our comparison in the direction opposite to our predictions. That is, if it is the degree of temporal lobe damage that matters, independent of which hemisphere is involved, we would expect the RHD signer to have more comprehension problems than the LHD signer. It is also important to point out that the RHD signer was congenitally deaf from birth and a native user of ASL: If native signers have a different brain organization for basic sign language comprehension than nonnative signers (e.g., if they rely more on right hemisphere structures), this RHD subject should have significant comprehension problems. A comparison of the performance of these two cases shows that the LHD signer was substantially impaired both on single sign and simple sentence comprehension, whereas the RHD signer was not (Fig. 4).

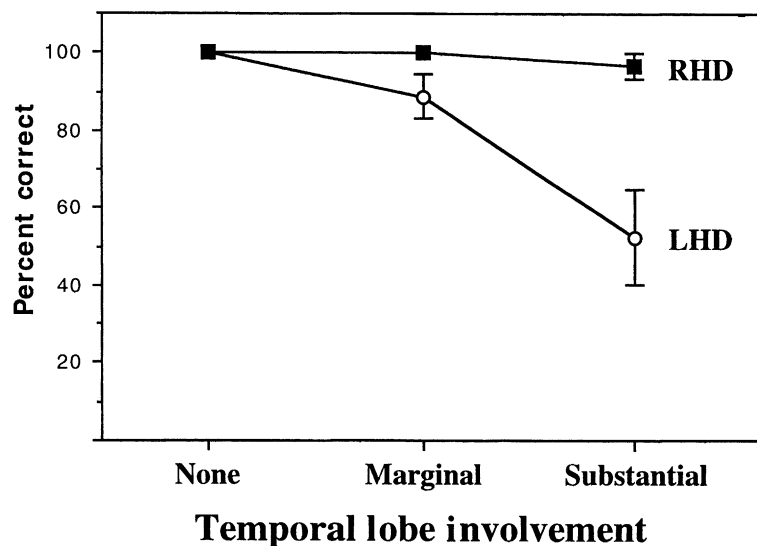


Fig. 3. Comprehension performance on the simple sentence comprehension task in left and right brain lesioned signers as a function of the degree of temporal lobe involvement. Note: there is only one data point in the RHD “marginal” cell and so statistical analyses were not carried out on the RHD data (see text). The RHD means are presented simply for visual comparison with the LHD group.

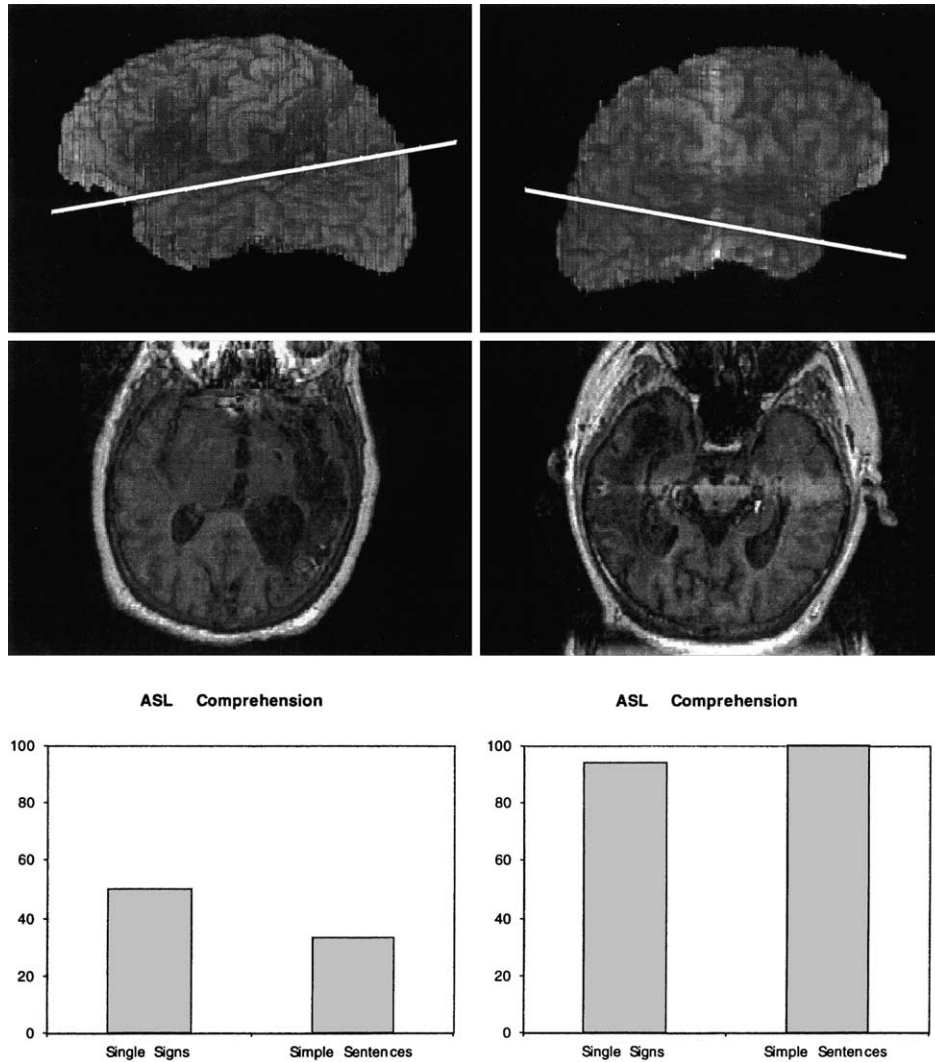


Fig. 4. Brain lesions as indicated by chronic MRI scans and comprehension scores (% correct) in one LHD and one RHD deaf signer. The level of the para-axial slice is indicated by the line on the surface reconstruction. In both cases the superior temporal lobe is substantially involved, particularly in the RHD signer whose lesion compromises the entire superior and middle temporal gyri. The distribution of the RHD signer's lesion corresponds to the right temporal lobe regions which were activated in the Neville et al. (1998) study. Despite the similar degree of temporal lobe and perisylvian damage in the two cases, only the LHD signer presents with significant impairment in ASL comprehension. The RHD case was congenitally and prelingually deaf and a native user of ASL.

3.1. Comparison with data from hearing/speaking subjects

Comprehension performance of even the RHD signers deteriorated with “complex” sentences. This suggests that right hemisphere (and extra-post-temporal left hemisphere) structures are recruited for comprehension under some circumstances. However, similar right hemisphere effects have been found in hearing-speaking populations (Caplan, Hildebrandt, & Makris, 1996; Swisher & Sarno, 1969). In fact, a comparison with previously published results (Swisher & Sarno, 1969) revealed that the performance of *hearing* RHD subjects on “simple” and “complex” sentences

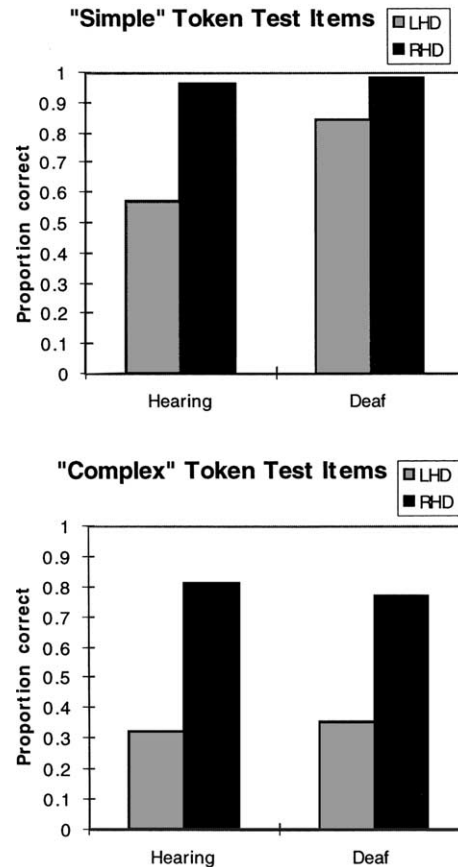


Fig. 5. Similar Token Test performance levels among hearing and deaf brain lesioned subjects. Hearing subject data taken from Swisher and Sarno (1969). Swisher and Sarno's parts I and II of the Token test are representative of our "simple" items and their parts III, IV, and V are representative of our "complex" items. Thus the mean proportion correct for I and II and III–IV was used to compare with our results. Note that the better performance of the deaf LHD signers compared with the hearing LHD individuals may stem from the fact that Swisher and Sarno selected only aphasics for inclusion in their LHD group, whereas our LHD group include some nonaphasic participants.

from the Token Test is virtually indistinguishable from that of the present deaf RHD subjects on similar items (Fig. 5).

4. Discussion

Several findings emerged from this study. First, LHD signers performed more poorly than RHD signers on every comprehension task used, including individual signs, simple sentences, and complex sentences. This supports earlier claims that ASL comprehension is predominately a function of the left hemisphere (Hickok, Say, Bellugi, & Klima, 1996b). Second, LHD signers with temporal lobe involvement were more impaired than LHD signers without temporal lobe involvement on all comprehension stimuli. This suggests that the left temporal lobe plays a particularly important role in ASL comprehension, just as it does in the comprehension of spoken language (Naeser et al., 1987). Third, the observed left–right

differences cannot be attributed solely to heterogeneity in language background in our study population (Corina, Neville, & Bavelier, 1998), as shown by case RHD-06, who was born deaf to deaf signing parents. RHD-06 had a large right perisylvian lesion, including substantial involvement of the temporal lobe yet had excellent ASL comprehension abilities. Fourth, although we did see some decrement in performance among RHD signers on the more complex sentence stimuli, this decline in performance is commensurate with what has been found previously in hearings/speaking RHD subjects (Swisher & Sarno, 1969). This finding is therefore inconsistent with the idea that systems which are crucial for ASL comprehension are more bilaterally organized than those for spoken language comprehension.

As noted, we found that LHD signers with temporal lobe involvement performed more poorly on ASL comprehension tasks than LHD signers without temporal lobe involvement. However, all the cases with temporal lobe involvement had lesions which extended into the parietal lobe or parietal and frontal lobes. It is therefore difficult, on the basis of this result alone to make the claim that comprehension deficits in LHD signers are predicted by the extent of temporal lobe damage alone rather than some combination of temporal and parietal/frontal damage. Limited evidence that the temporal lesion is critical in producing comprehension impairment comes from the observation in the present study that even large frontal (LHD03) or large frontoparietal (LHD01) lesions do not cause substantial comprehension deficits when temporal lobe structures are spared (or largely spared in the case of LHD01). What we can conclude then, is that left temporal lobe damage is a necessary condition for producing ASL comprehension deficits (especially for relatively simple sentence stimuli) following unilateral stroke. It remains to be established unequivocally in lesion studies whether it is a sufficient condition. However, functional imaging results help constrain the interpretation of our data: none of the published reports on sign language comprehension indicate parietal lobe activation, although frontal activation has been reported (Neville et al., 1998; Söderfeldt, Rönnerberg, & Risberg, 1994); our own unpublished fMRI data corroborates these observations. A reasonable conclusion, then, is that parietal lobe structures do not play a significant role in ASL comprehension. Frontal systems have been implicated in aspects of sentence comprehension in hearing individuals (Caramazza & Zurif, 1976; Stromswold, Caplan, Alpert, & Rauch, 1996). The nature of its contribution is still being debated, but it is generally acknowledged that the bulk of the auditory language comprehension work is carried out by left posterior systems with frontal systems playing a smaller role (Damasio, 1992; Kertesz, Lau, & Polk, 1993; Naeser et al., 1987). Based on the parallels between deaf and hearing patients with respect to the types of aphasic syndromes and their associated lesions (Hickok et al., 1998a), we hypothesize a similar relation between the left temporal and left frontal systems in the comprehension of sign language.

Taken together, all of the available data point to a very similar neural organization of signed compared with spoken language comprehension. The left hemisphere is clearly dominant, and within the left hemisphere, systems in the temporal lobe appear to play the largest role. Apparent discrepancies in the findings of lesion versus functional imaging studies are likely attributable to differences in the kinds of information one gains from these methodologies: functional imaging studies provide information about the range of neural structures which are active (and presumably participate) during the performance of a given task, whereas lesion studies provide information about which structures are *critical* for the performance of a given task.

References

- Binder, J. R., Rao, S. M., Hammeke, T. A., Yetkin, F. Z., Jesmanowicz, A., Bandettini, P. A., Wong, E. C., Estkowski, L. D., Goldstein, M. D., Haughton, V. M., & Hyde, J. S. (1994). Functional magnetic resonance imaging of human auditory cortex. *Annals of Neurology*, *35*, 662–672.
- Brownell, H. H., Potter, H. H., Bihle, A. M., & Gardner, H. (1986). Inference deficits in right brain-damaged patients. *Brain and Language*, *27*, 310–321.
- Caplan, D., Hildebrandt, N., & Makris, N. (1996). Location of lesions in stroke patients with deficits in syntactic processing in sentence comprehension. *Brain*, *119*, 933–949.
- Caramazza, A., & Zurif, E. B. (1976). Dissociation of algorithmic and heuristic processes in sentence comprehension: Evidence from aphasia. *Brain and Language*, *3*, 572–582.
- Corina, D. (1998). The processing of sign language: Evidence from aphasia. In *Handbook of neurolinguistics* (pp. 313–329). San Diego: Academic Press.
- Corina, D. P., Neville, H. J., & Bavelier, D. (1998). Response from Corina, Neville and Bavelier. *Trends in Cognitive Sciences*, *2*, 468–470.
- Damasio, A. R. (1992). Aphasia. *New England Journal of Medicine*, *326*, 531–539.
- DeRenzi, E., & Vignolo, L. A. (1962). The token test: A sensitive test to detect receptive disturbances in aphasics. *Brain*, *85*, 665–678.
- Goodglass, H., & Kaplan, E. (1983). *The assessment of aphasia and related disorders* (second ed.). Philadelphia: Lea & Febiger.
- Hickok, G., Bellugi, U., & Klima, E. S. (1998a). The neural organization of language: Evidence from sign language aphasia. *Trends in Cognitive Sciences*, *2*, 129–136.
- Hickok, G., Bellugi, U., & Klima, E. S. (1998b). What's right about the neural organization of sign language?: A perspective on recent neuroimaging results. *Trends in Cognitive Science*, *2*, 465–468.
- Hickok, G., Klima, E., Kritchevsky, M., & Bellugi, U. (1995). A case of “sign blindness” following left occipital damage in a deaf signer. *Neuropsychologia*, *33*, 1597–1606.
- Hickok, G., Klima, E. S., & Bellugi, U. (1996a). The neurobiology of signed language and its implications for the neural basis of language. *Nature*, *381*, 699–702.
- Hickok, G., Say, K., Bellugi, U., & Klima, E. S. (1996b). The basis of hemispheric asymmetry for language and spatial cognition: Clues from focal brain damage in two deaf native signers. *Aphasiology*, *10*, 577–591.
- Hickok, G., Wilson, M., Clark, K., Klima, E. S., Kritchevsky, M., & Bellugi, U. (1999). Discourse deficits following right hemisphere damage in deaf signers. *Brain and Language*, *66*, 233–248.
- Kertesz, A., Lau, W. K., & Polk, M. (1993). The structural determinants of recovery in Wernicke's aphasia. *Brain and Language*, *44*, 153–164.
- Kimura, D. (1981). Neural mechanisms in manual signing. *Sign Language Studies*, *33*, 291–312.
- Mazoyer, B. M., Tzourio, N., Frak, V., Syrota, A., Murayama, N., Levrier, O., Salamon, G., Dehaene, S., Cohen, L., & Mehler, J. (1993). The cortical representation of speech. *Journal of Cognitive Neuroscience*, *5*, 467–479.
- Naeser, M. A., Helm-Estabrooks, N., Haas, G., Auerbach, S., & Srinivasan, M. (1987). Relationship between lesion extent in ‘Wernicke's area’ on computed tomographic scan and predicting recovery of comprehension in Wernicke's aphasia. *Archives of Neurology*, *44*, 73–82.
- Neville, H., Bavelier, D., Corina, D., Rauschecker, J., Karni, A., Lalwani, A., Braun, A., Clark, V., Jezzard, P., & Turner, R. (1998). Cerebral organization for language in deaf and hearing subjects: Biological constraints and effects of experience. *Proceedings of the National Academy of Sciences of the USA*, *95*, 922–929.
- Paulesu, E., & Mehler, J. (1998). Right on in sign language. *Nature*, *392*, 233–234.
- Poizner, H., & Kegl, J. (1993). Neural disorders of the linguistic use of space and movement. *Annals of the New York Academy of Sciences*, *682*, 192–213.
- Poizner, H., Klima, E. S., & Bellugi, U. (1987). *What the hands reveal about the brain*. Cambridge, MA: MIT Press.
- Schlosser, M. J., Aoyagi, N., Fulbright, R. K., Gore, J. C., & McCarthy, G. (1998). Functional MRI studies of auditory comprehension. *Human Brain Mapping*, *6*, 1–13.
- Söderfeldt, B., Rönnerberg, J., & Risberg, J. (1994). Regional cerebral blood flow in sign language users. *Brain and Language*, *46*, 59–68.
- Stromswold, K., Caplan, D., Alpert, N., & Rauch, S. (1996). Localization of syntactic comprehension by positron emission tomography. *Brain and Language*, *52*, 452–473.
- Swisher, L. P., & Sarno, M. T. (1969). Token Test scores of three matched patient groups: Left brain-damaged with aphasia, right brain-damaged without aphasia, non-brain damaged. *Cortex*, *5*, 264–273.
- Wapner, W., Hamby, S., & Gardner, H. (1981). The role of the right hemisphere in the apprehension of complex linguistic materials. *Brain and Language*, *14*, 15–33.